

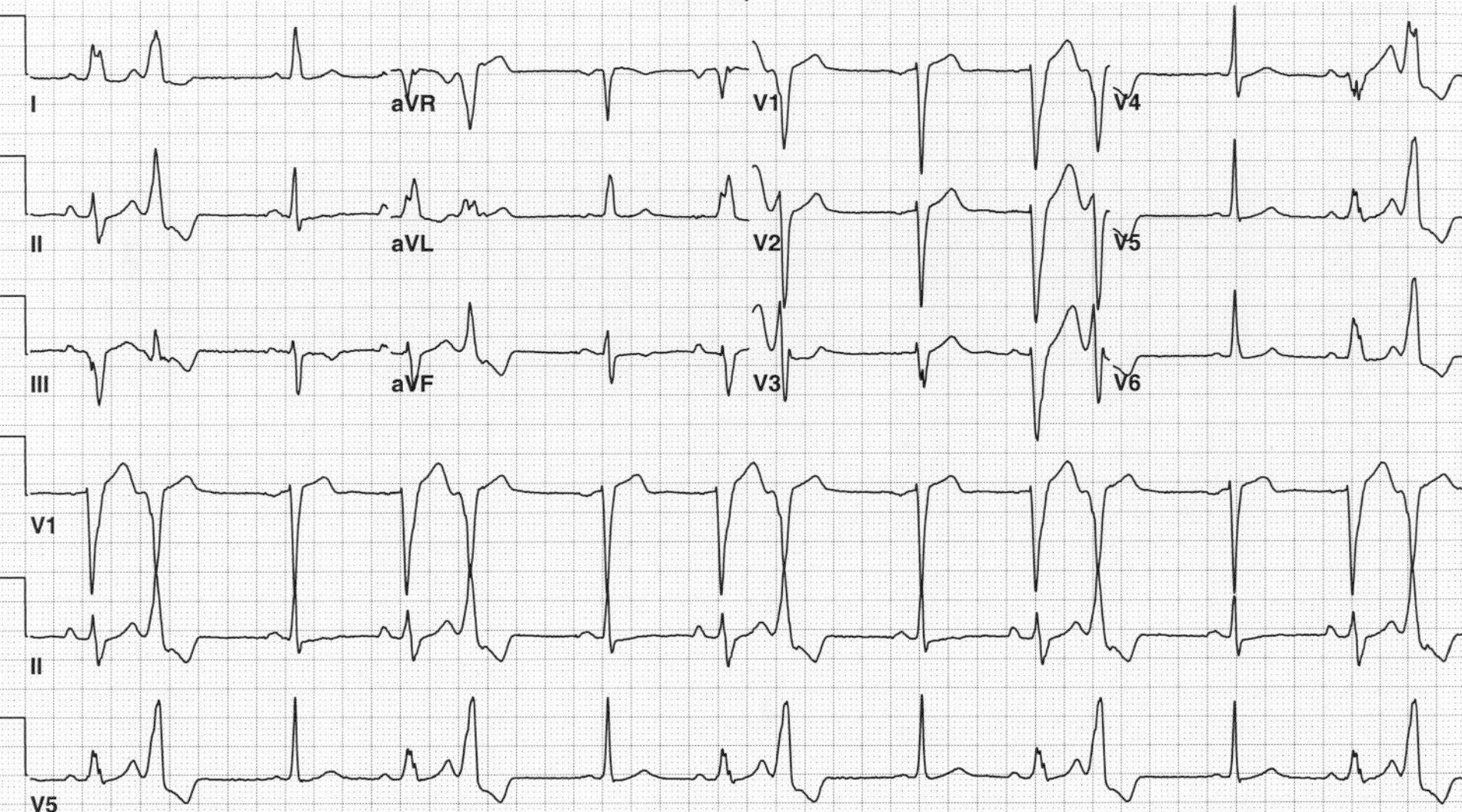
13-JAN 11:10:47

04 yr
Male Hispanic

Vent. rate 85 BPM
PR interval 148 ms
QRS duration 90 ms
QT/QTc 386/459 ms
P-R-T axes 64 -39 70

MARKED SINUS BRADYCARDIA WITH FREQUENT PREMATURE VENTRICULAR
COMPLEXES
OTHERWISE NORMAL ECG

Referred by:



29-JUN 14:01:00

93 yr
Male

Hispanic

Vent. rate	64	BPM
PR interval	172	ms
QRS duration	112	ms
QT/QTc	420/433	ms
P-R-T axes	-5 13	38

NORMAL SINUS RHYTHM
NONSPECIFIC INTRAVENTRICULAR BLOCK
ABNORMAL ECG

Confirmed

